

# IMMUNITY IN TOXOPLASMOSIS<sup>1</sup>

J. K. Frenkel<sup>2</sup>

*Toxoplasma commonly infects animals and man in the Americas. The following article applies what is currently known about toxoplasmosis immunology to provide a theoretical explanation of the relatively common subclinical form of the infection as well as the diverse but relatively rare forms of overt clinical disease.*

## General Immunologic Considerations

Asymptomatic *Toxoplasma* infection of both man and animals is common in the Americas. This is shown by the high prevalence of *Toxoplasma* antibody, commonly found in 50-60% of human subjects 20-30 years old, in the absence of apparent clinical disease (1). Similarly, serologic surveys have found antibody in normal animals (2). Clinical illness also occurs, however, such as the illness that led to Splendore's discovery of *Toxoplasma* in a spontaneously diseased rabbit at the Portuguese Hospital in São Paulo (3). In this vein, postmortem examination of babies and adults was instrumental in recognizing neonatal and adult toxoplasmosis in Latin America (4, 60).

What immunologic insights can be drawn from the simultaneous presence of asymptomatic, clinical, and even fatal infections in animals and man? (It seems appropriate to start with a brief general discussion of toxoplasmosis immunology, because that is basic to an understanding of clinical toxoplasmosis, its diagnosis, and its optimal treatment.) Regarding man, Table 1 compares diverse human immunologic responses to *Toxoplasma* infection, grouping these

into seven clinical responses that can be usefully discussed. Regarding most animals, it is important to note that immunity is readily developed but infection persists, leading to a huge reservoir of chronically infected animals that serve as intermediate hosts, thus maintaining the infection in nature (Figure 1).

Judging from the marked pathogenicity of *Toxoplasma* for Australian animals that evolved without native cats, and for the arboreal squirrel and night monkeys (*Saimiri* and *Aotus* spp.) in Panama, whereas ground-dwelling animals were resistant (2), it is reasonable to postulate that animals exposed to *Toxoplasma* oocysts in the soil were selected for their ability to develop immunity in a timely fashion. (The life-cycle of *Toxoplasma* and other aspects of the parasite are discussed elsewhere—5,6,7.) Humans acquire infection either from cat-shed oocysts, which persist in the soil for long periods of time, or from eating undercooked meat of chronically infected animals (Figure 2).

Protective immunity to *Toxoplasma* is specific and is mediated by antibody, T-lymphocytes, and their products. Several classes of antibody, active against several antigens, have been described. All of them develop within a few days after infection.

Some of these antibodies cause *Toxoplasma* lysis, as demonstrated by the dye test of Sabin and Feldman (8). These antibodies, which act only on extracellular *Toxoplasma*, cause perforation of the cell membrane in the presence of complement (9), producing leakage of the cytosol (10). However, while protection experiments have shown that a few lethal doses of

<sup>1</sup>Based on a paper presented at an immunoparasitology conference organized by the Wake Forest University and Universidad de Antioquia that was held in Medellín, Colombia, in July 1983. The investigations reported here were supported in part by Grant #AI-7489 from the National Institute of Allergy and Infectious Diseases, U.S. National Institutes of Health. This article is also to be published in Spanish in the *Boletín de la Oficina Sanitaria Panamericana*, 1986.

<sup>2</sup>Professor of Pathology, University of Kansas Medical Center, Kansas City, Kansas 66103, U.S.A.

Table 1. The clinical and subclinical immunologic spectrum of human toxoplasmosis.

	Deferred clinical toxoplasmosis (subclinical in mother, clinical in baby)	Threshold	Acute	Subacute	Chronic infection	Recrudescence in immunosuppressed host	Subclinical toxoplasmosis (inapparent infection)
Manifestations	<i>Mother:</i> From none to threshold clinical manifestations <i>Baby:</i> Hepatitis, pneumonia, encephalitis, retinochoroiditis (see subacute clinical toxoplasmosis)	Fever, lymphadenopathy	Pneumonia, hepatitis, myocarditis, myositis encephalitis, and retinochoroiditis		Retinochoroiditis	Encephalitis, (myocarditis, pneumonia, retinochoroiditis)	None
Typical serologic findings	Seroconversion with high antibody titers in IgM and IgG fractions	Seroconversion, high IgM and IgG titers		High IgM and IgG titers	Intermediate to low IgG titers	Varied IgG titers Variable or absent IgM titers	Stable IgG titers Variable or absent IgM titers
Immunologic factors and status	a) Age resistance (mother) b) Immunologic immaturity (baby) c) Passive immunization (baby)	a) Near optimal acquired immunity	a) Delayed/inadequate rate of immunity acquisition	a) Inadequate rate of immunity acquisition b) Immunologic immaturity c) Passive immunization d) Immunologic basis of periventricular necrosis	a) Cyst rupture with necrosis from delayed hypersensitivity ~ 90% b) Localized immune defect in retina with multiplying tachizoytes (~ 10%) c) Established immunity elsewhere in the body	a) Immune defect due to lymphoma, tumor chemotherapy, AIDS, other	Established immunity probably with pre-munition

Figure 1. Transmission of *Toxoplasma*, including natural and farm-human cycles. The three important *Toxoplasma* reservoirs are cats, the soil, and intermediate hosts. From J. K. Frenkel (7), p. 1190.

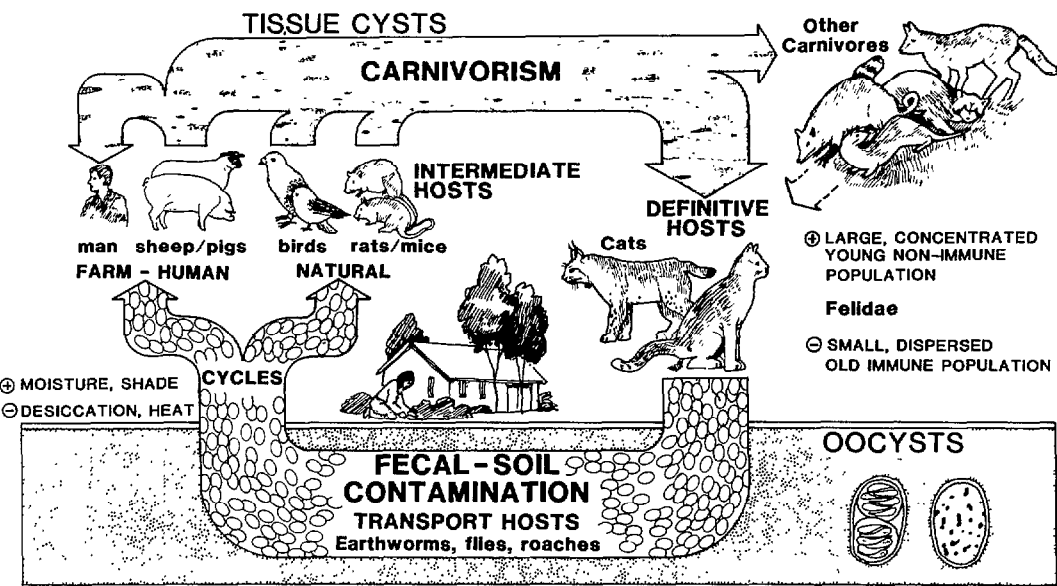
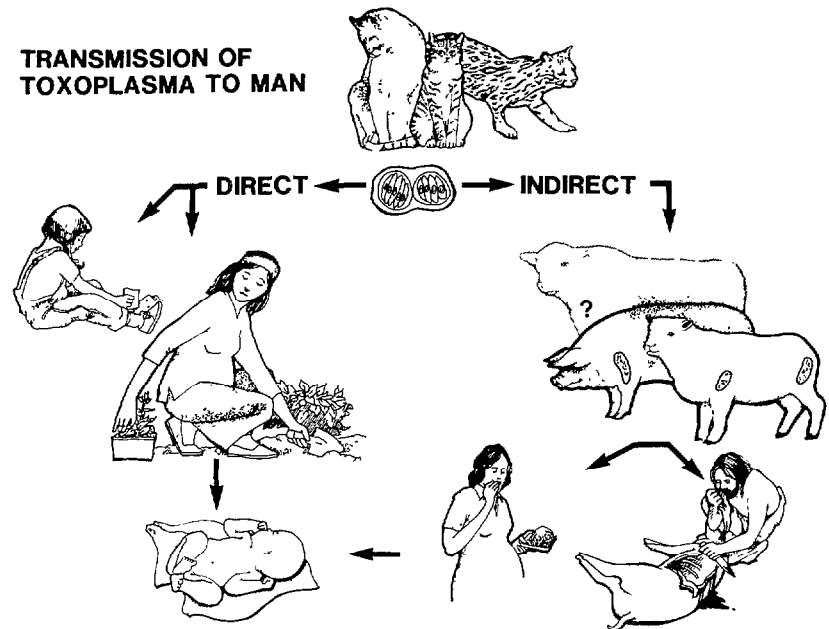


Figure 2. Transmission of *Toxoplasma* to man. All human infections arise directly or indirectly from oocysts shed by cats. People either ingest oocysts directly with soil contaminated by cat feces, or else become infected indirectly by eating the undercooked flesh of animals that have eaten oocysts. Infection of the fetus can follow maternal infection acquired by either route. From J. K. Frenkel *Microbiology*, 1984, pp. 212-217.



*Toxoplasma* organisms may be overcome by such "passively transferred" antibodies, these antibodies rarely cause appreciable modification of severe experimental infection (11). That may be partly because tachyzoites can enter adjacent cells without being exposed to antibody, and also because tachyzoites in the bloodstream are often transported within white blood cells. However, passively transferred antibodies do add to the effect of cellular immunity, as shown by studies in IgM-suppressed mice (12).

The most important specific factor in protective immunity is supplied by sensitized lymphoid cells, which have been shown to confer immunity by adoptive cell transfer (11). By separately testing specifically and nonspecifically immune lymphocytes in combination with macrophages, the lymphocytes in these suspensions were shown to play a decisive role (13). Other experiments showing exquisite sensitivity, to 50 rads and to small concentrations of cortisol, supported the concept that specifically committed lymphocytes were decisive (14).

That T-lymphocytes were involved was suggested by the inability of athymic, nude mice to develop immunity, and also by the fact that this defect was repaired by thymic transplants (15). In addition, the fact that established immunity in hamsters could be abolished by pharmacologic doses of corticosteroids, even in the presence of high antibody levels, was consistent with the theory that T-lymphocytes played the essential role (16,17).

Another noteworthy point is that human lymphocyte products have been shown to inhibit the multiplication of *Toxoplasma* in macrophages (18,19), and at least two types of mediators have been studied in the supernatants of lymphocytes from immune animals. Regarding the latter, a *Toxoplasma* inhibitory factor with a molecular weight between 40,000 and 80,000 daltons was derived from mouse lymphocytes. This factor, which has been studied mainly in mouse macrophages (20,21), has also been found active in mouse kidney cells (22). What appears to be another *Toxoplasma* immune mediator with a molecular weight between 4,000 and 5,000 daltons was derived from hamster lymphocytes

studied in macrophages, kidney cells, and fibroblasts (23). In this instance, separate *Toxoplasma* and *Besnoitia* immune mediators were found in hamster lymphocyte supernatants. Each was specific, though with some nonspecific admixtures. The mouse mediators mentioned have not been tested for microbe specificity. However, in several of these supernatants immune interferon qualities were detected, suggesting that although specifically induced, some mediator in the supernatant is nonspecifically expressed. A more detailed comparison of several mediators has been published elsewhere (24).

A number of nonspecific immune factors should also be considered. Alpha interferon was active in some studies (25) but inactive in others (26). Phagocytosis and killing by activated macrophages was found highly effective but nonspecific, whereas committed lymphocytes or antibody conferred specificity on them (27). An oxidative metabolic burst has been found to accompany phagocytosis and to precede killing of *Toxoplasma* by reactive oxygen metabolites in macrophages (28). Interferon-gamma was identified as the lymphokine (also called macrophage activating factor—MAF), which stimulated macrophages to release peroxides and kill *Toxoplasma* (29). In cultured fibroblasts, interferon-gamma induced degradation of tryptophane, restricting the growth of *Toxoplasma* (especially in Eagle's medium, which contains only 10 µg/ml of tryptophane). At higher concentrations of tryptophane, higher concentrations of interferon were needed to produce demonstrable anti-*Toxoplasma* activity (30).

Although all these factors may participate to some degree in the immune concert *in vivo*, it is important to recall that unlike *Leishmania* and *Histoplasma*, *Toxoplasma* infects principally non-macrophages. Histopathologic studies, cinematography (31), and electron microscopy (32) have all shown that *Toxoplasma* actively invades hepatic cells, fibroblasts, myocardial cells, smooth muscle cells, endothelial cells, neurons, and intestinal as well as other epithelial cells in both experimental animals and man. Therefore, it is important to explain immunity in nonmacrophages, which are unlikely to release oxygen metabolites. The blockage of *Toxoplasma* growth by interferon-

gamma, mediated by degradation of tryptophane, is a mechanism that might be operative in a malnourished host (the normal concentration of tryptophane in blood is approximately 7  $\mu\text{g/ml}$ ). However, nonspecific protection induced by *Listeria* and *Besnoitia* protected only against 10 *Toxoplasma* or less, whereas specific immunity protected against more than 100,000 *Toxoplasma* (33). It is this latter order of magnitude of specific protection that we must strive to explain immunologically.

Most strains of *Toxoplasma* have low pathogenicity for most hosts (34). The immunity that follows acute infection is usually associated with persistent infection, a state called concomitant immunity (35) or premunition (36). Premunition is the best state of immunity most hosts are able to achieve and also involves circumstances that enable the parasite to ensure its survival in nature. Until recently it remained uncertain whether chronic persistent *Toxoplasma* infection was necessary for the maintenance of immunity. Vaccination of mice with killed *Toxoplasma*, while generating antibodies, usually did not protect them against acutely fatal infection (37); but guinea pigs and hamsters (which develop immunity more readily) or mice given a threshold fatal dose could sometimes be protected (38,39,40). Recently, a nonpersisting *Toxoplasma* strain (ts-4) was discovered (41) that confers immunity on mice, hamsters, rabbits, and certain monkeys (37,40,42,43). Apart from providing a good candidate for a vaccine, strain ts-4 also permits study of *Toxoplasma* immunity without premunition.

### Patterns of Human Disease and Immunity

On the basis of the foregoing, one can attempt to analyze the various immune factors operative in individual human disease syndromes (see Table 1).

#### *Deferred Clinical Toxoplasmosis*

This affects 20 to 40% of the infants born to women infected during pregnancy. The women

remain asymptomatic but infect some of their babies in utero. Although both mother and infant are infected with the same *Toxoplasma* strain, and although there is passive transfer of anti-*Toxoplasma* IgG from mother to fetus, the outcome is neonatal illness in about 30% of the cases.

It is well-known, of course, that most adult humans develop immunity quickly—before lesions, signs, or symptoms develop. However, most human infants infected in utero, while not necessarily symptomatic at birth, acquire such a heavy parasite load that they eventually develop retinochoroiditis (44). This natural experiment illustrates immunologic maturity and immaturity, conditions that can also be observed in rats (45), cats (46), and chickens (47).

Whereas one can expect that common *Toxoplasma* infections are asymptomatic because animals and man have been selected for their ability to develop immunity, there is usually an age range where such immunity matures. In rats, this time arrives about two weeks after birth (45); in chickens it comes about two days after hatching (47); in kittens it comes at about three months (46); and in human babies it arrives at six to 12 months—all of these being times when the likelihood of exposure to oocysts or tissue cysts in nature appears to be increasing.

#### *Threshold Clinical Toxoplasmosis*

This is experienced by children and adults who pass through acute toxoplasmosis with only a slight fever, a mild "flu," or lymphadenopathy. These patients are rarely diagnosed except when detected during an epidemiologic investigation triggered by more severe illness. Good examples of such infections have been reported from outbreaks at an Atlanta riding stable (48) and in the Panamanian jungle (49). In both outbreaks, the infection was thought to have been acquired by exposure to oocysts. However, only three of seven laboratory infections (50) produced threshold symptoms, the remaining four being entirely asymptomatic. Moreover, during a ten-year study of a Panamanian population (51) we encountered 55 seroconversions, but none of the

individuals involved reported any illness that could be linked with *Toxoplasma* infection.

Lymphadenopathy with lymphoreticular hyperplasia (52,53) is usually a manifestation of developing immunity. Sometimes a preceding acute illness is apparent (54). Few organisms are found in affected lymph nodes, and cysts are usually present; antibody titers are usually high (55). Histologically, the picture is distinct from a lymphoma (52,56), although on occasion acute toxoplasmosis will occur in a patient with incipient lymphoma (57).

### *Acute Clinical Toxoplasmosis*

This is typically a severe, acute, generalized illness, often with pronounced focal lesions of the lung, liver, heart, brain, or skeletal muscles, which can have a fatal outcome. There have been numerous clinically and serologically suspected cases, some with histopathologic confirmation. Both children (58) and adults (59,60) are afflicted.

Sometimes, the circumstances of a case suggest reasons for a defect in the characteristic natural resistance. One patient had concomitant bartonellosis (60). Several patients were of an advanced age (61), a condition that has been linked with decreasing resistance in mice (62). A few were immunosuppressed when they became infected, either as a result of tumor chemotherapy (63,64) or after a kidney or (especially) a heart transplant (65).

### *Subacute Toxoplasmosis*

This is an infection acquired in utero that is symptomatic for a prolonged period in the immunologically immature fetus, despite exposure to maternal antibody. As Desmonts and Couvreur have pointed out (66), when *Toxoplasma* is transmitted in the second trimester it produces more severe clinical illness than when it is transmitted during the third trimester; however, transmission is more common in the latter period.

Studies by Eichenwald (67) have differentiated between generalized and central nervous

system disease. The generalized disease occurs initially and then may lead to encephalitis. Diffuse encephalitis and periventricular necrosis are common in the United States and Europe, but in a group of cases I was able to review in Costa Rica, periventricular necrosis was not present.

Periventricular necrosis starts as ependymal ulcerations caused by tachyzoites and progresses to vasculitis unassociated with *Toxoplasma* organisms. This uniform periventricular vasculitis, together with thrombosis, suggested the hypothesis that antigen found trapped in the three ventricles rostral to the obstructed aqueduct interacts with hematogenous antibody, a development that leads to vasculitis based on an *in vivo* antigen-antibody reaction (68). Thrombosis of the affected vessels then results in the periventricular necrosis. A toxic reaction was excluded by the observation that cell damage was absent in the ventricular lumen, where granulation tissue could be found to emanate from the walls of larger thrombosed arteries that had escaped complete necrosis.

The development of internal hydrocephalus secondary to aqueduct obstruction and accentuated by inflammation and leakage of plasma protein into the ventricles carries a serious prognosis. In children that survive, a spectacular pattern of intracerebral calcification may be found, such as curvilinear calcium deposits marking the necrotic foci in the ventricular walls and elsewhere. Antibody is believed to be formed actively by the fetus, starting in the second half of intrauterine life; and this, together with passively diffused maternal antibody, is probably instrumental in mitigating the visceral lesions. However, brain and retinal lesions progress despite high antibody titers (69). Nothing is known about cellular immunity in the fetal or neonatal brain.

### *Chronic Toxoplasmosis*

A complication of chronic *Toxoplasma* infection, this condition is believed to persist in most humans after the acute infection has passed. The best evidence of chronic persistence has been

obtained from animals, in which *Toxoplasma* cysts can be found histologically and by animal inoculation for months and years in most hosts except cattle. Considering the life-cycle of *Toxoplasma*, chronic infection of the intermediate host is essential because the tissue cyst transmits the infection more efficiently to cats than the oocyst (70).

Cyst persistence has been selected for, ever since *Toxoplasma* became a two-host coccidian. Cysts are found in the brain, in skeletal and cardiac muscles, and in many other organs, with each cyst containing hundreds or thousands of bradyzoites (slowly multiplying organisms) (71). With the attrition of the cysts, and in the presence of delayed-type hypersensitivity, adjacent cells are destroyed as well. Clinically significant lesions are found mainly in the retina, probably as a result of the highly concentrated structure-function relationship and the lack of retinal regenerative capacity.

Most retinal lesions in man are self-limited, even without chemotherapy (68). From a hamster model it was learned that the attrition of cysts in the retina also leads to inflammatory lesions and scarring, even without the proliferation of tachyzoites. Because of these observations, the "cyst rupture lesion" hypothesis was developed, based on antigen release in the presence of delayed-type hyper sensitivity, but with enough immunity to inhibit proliferation of tachyzoites (68). In both humans and hamster models a small number of tachyzoite-produced lesions have also been described, suggesting the theory that an immune defect exists in the retinas of these cases.

Considering the dual pathogenesis of toxoplasmic retinochoroiditis, I estimate 90% of the cases to result from cyst rupture, with the lesions being caused by hypersensitivity in the presence of adequate immunity, and 10% to result from tachyzoite proliferation producing necrosis of individual parasitized cells consequent to a localized immune defect. Because corticosteroids are often used clinically to diminish the inflammation of hypersensitivity, it should be pointed out that immunosuppression is also likely to result from such anti-inflammatory doses of cor-

ticosteroids. In this case, should another cyst disintegrate, the released bradyzoites might not be killed and might proliferate as tachyzoites, actively destroying the retinal cells parasitized. For this reason, the administration of anti-inflammatory doses of corticoids for ocular toxoplasmosis should always be accompanied by chemotherapy with sulfadiazine and pyrimethamine, which inhibit parasite proliferation (68).

### *Recrudescence or Relapsing Toxoplasmosis*

This condition characterizes focal lesions, usually in the brain but occasionally in the retina or myocardium, where large numbers of tachyzoites destroy cells that they have parasitized. Recrudescence toxoplasmosis is characteristically found in patients who are immunosuppressed—e.g., patients with lymphoma, subjects undergoing tumor chemotherapy, transplant recipients, or patients with the Acquired Immune Deficiency Syndrome (AIDS).

The cerebral lesions are spherical necrotic foci showing hemorrhagic borders histologically. They are seen as target-shaped or ring-shaped lesions on computerized axial tomograms. They are sometimes called abscesses, but contain no pus. In the immunosuppressed host, cyst rupture with liberation of bradyzoites leads to parasitization of surrounding cells, large numbers of proliferating tachyzoites, and expanding lesions. In at least one patient, a similar ocular lesion has been described (72), this occurring in a woman on long-term therapy with corticosteroids partly injected under Tenon's capsule.

The typically focal, relapsing toxoplasmosis can be distinguished from the primary infection in immunosuppressed hosts, which is generalized. It can be expected that with more profound immunosuppression in AIDS, additional foci are likely to be found in other organs (73).

Relapsing toxoplasmosis lesions have been studied experimentally in hamsters and compared with human lesions (16,17,68), and a large series of toxoplasmosis cases in immunosuppressed humans has been reviewed (74). Localization of the condition in the brain is believed to result from cysts situated there. However, the

principal pathogenetic factor is a pronounced immune defect of the central nervous system that permits the organisms to multiply. It has also been suggested that organisms may reach the brain hematogenously. This is unlikely, however, because there is usually no extraneural source of toxoplasmic proliferation; also, because antibody and complement are generally present in these patients, neutralization of at least the extracellular *Toxoplasma* disseminated by the bloodstream could be expected. Chemotherapy with sulfadiazine and pyrimethamine is effective in such immunosuppressed patients because it acts directly on the multiplying tachyzoites (17,68).

### *Inapparent Infection*

This condition is found in a large group of people and animals with stable antibody titers, usually only in the IgG fraction, without clinical manifestations. As suggested in the discussion of premunition, many of these subjects probably remain infected, as shown by positive passages in animals (71). The presence of an effective infection-immunity has also been inferred from observation of asymptomatic experimental animals. However, treatment with large doses of corticoids and certain antineoplastic agents can abolish immunity in both animals and man (16,17), so that people with inapparent infections are at risk for recrudescence or relapsing toxoplasmosis.

However, human immunity to *Toxoplasma* is apparently more stable to given states of hypercorticism than is immunity to cytomegalovirus, because there are far fewer relapses of toxoplasmosis than of cytomegalovirus infection. In this regard it is worth noting that *Toxoplasma* has been isolated from a number of immunosuppressed people at autopsy without finding lesions (17,75).

The prevalence of inapparent infection is lower in the United States than in Latin America, and particular age groups in the United States tend to have lower mean antibody titers than Latin American counterparts. These circum-

stances are attributed to lower rates of infection and reinfection in the United States (1).

The prevalence of antibody in Costa Ricans between 15 and 25 years of age is about 60%. The most common antibody titer is 1:1000, with about a quarter of the seropositive people having this or higher titers. Because such levels are in the range of those associated with clinical toxoplasmosis, it is important to distinguish between toxoplasmosis and unassociated disease.

Figure 3 shows how IgM antibody titers can be used to evaluate the meaning of high IgG titers. Also, pregnant women with high titers need to be tested so as to differentiate between recent acute maternal infection (during which the fetus may have become infected) and a previously contracted inapparent infection (in which case the mother's immunity apparently protects the fetus). Figure 4 outlines a way of dealing with this problem by using the antibody titer determination in the IgM fraction; if necessary, such work should be performed in conjunction with efforts to isolate the organism and studies for the presence of antigenemia. The treatment has been discussed in a recent symposium on toxoplasmosis (78).

### *Vaccine Development*

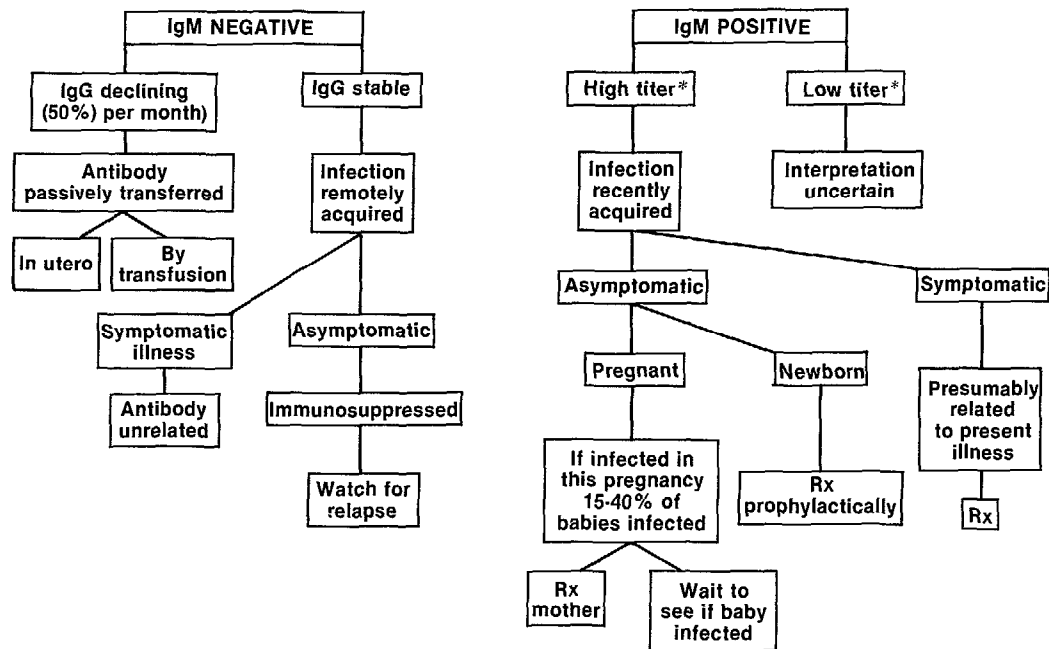
The foregoing discussion of immunity would be incomplete without briefly covering the potential for immunization. In man and most animals a vaccine would be useful if it prevented illness or the transmission of *Toxoplasma* to the highly susceptible fetus. With the availability of many strains of low pathogenicity, immunity is easily achieved. However, the danger of recrudescence occurring as a potential consequence of vaccination is not acceptable.

A mutagenized strain of *Toxoplasma*, ts-4, has been found to immunize animals but to persist no more than one or two months in mice and hamsters (37,40,41). Experiments are in progress to test the effectiveness and safety of ts-4 vaccine.

Cats usually develop resistance to *Toxoplasma*-related illness by the time they are weaned, but

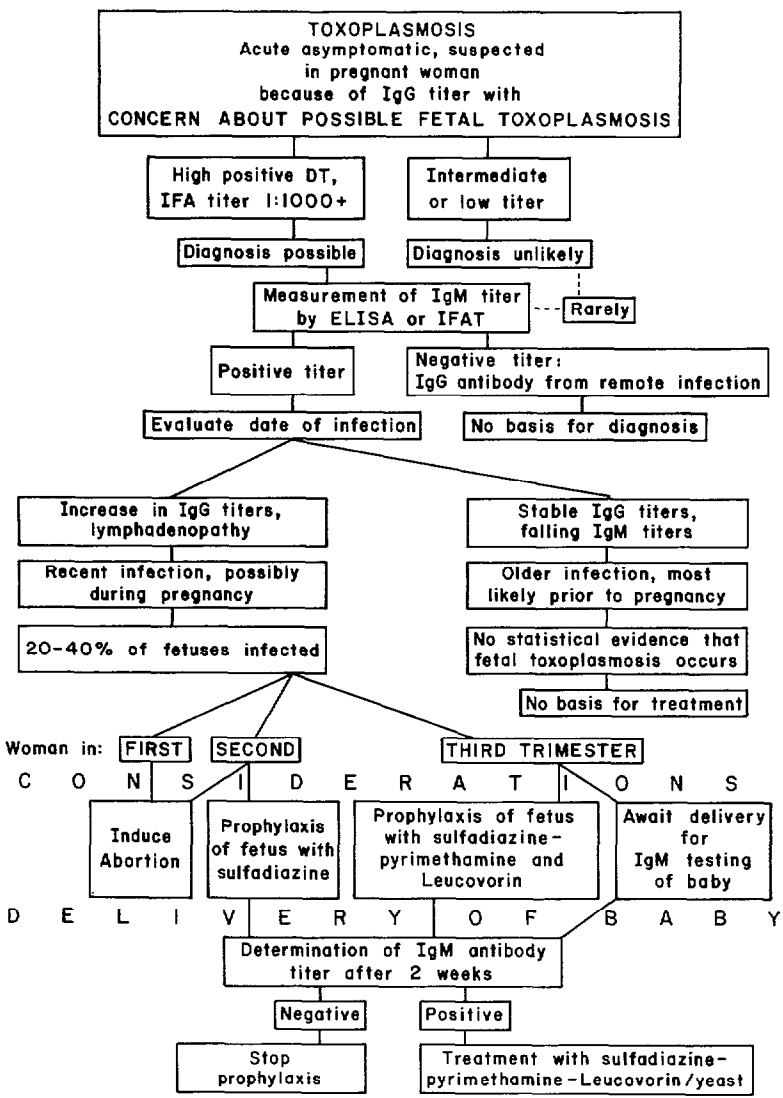


Figure 3. A method for analyzing IgG antibody to *Toxoplasma* in terms of IgM titers obtained with the immunofluorescent antibody (IFA) or enzyme-linked immunosorbent assay (ELISA) test.



\*Interpretation depends on the type of test employed. In the IgM—immunofluorescent antibody test, a titer of 1:64 would support a diagnosis of infection acquired one to three months earlier. In the double-sandwich IgM-ELISA (IgM capture) test, titers of 1:256 and higher should be expected in the first months of infection. (Y. Naot et al.—55).

Figure 4. Algorithm for pregnant women with antibody to *Toxoplasma*. From J. K. Frenkel (78).



they still shed large numbers of oocysts after their first infection with bradyzoites in tissue cysts (46). Cystless strains of *Toxoplasma* and killed vaccine have failed to immunize cats against oocyst shedding (76). However, cats treated with monensin (a non-ionic carboxylic ionophore used in chickens and cattle as a cocci-

diostat and to improve utilization of food) could be immunized without shedding oocysts in the process (77).

Efforts are underway to estimate the cost of toxoplasmosis in several countries, along with the cost-effectiveness of hygienic measures and of vaccination used for its prevention.

## SUMMARY

This article reviews what is currently known about toxoplasmosis immunology and relates that information to the various clinical and subclinical responses to *Toxoplasma* infection.

In brief, the text notes that *Toxoplasma* infection readily elicits an immunity that has been shown to depend principally on T-cell factors and to a lesser degree on antibody. The latter lyses extracellular *Toxoplasma* in the presence of complement, but is not effective against the organisms that multiply intracellularly in a variety of cells—including fibroblasts, muscle cells, neurons, and liver cells. A mediator derived from T-lymphocytes has been found active against *Toxoplasma* in fibroblasts and kidney cells.

The common subclinical asymptomatic infection in mammals, birds, and man is dependent upon an effective immunity. The various disease conditions derived from *Toxoplasma* infection include deferred clinical toxoplasmosis, in which an asymptomatic mother infects her fetus (in whom illness is often apparent), as well as threshold, subacute, acute, chronic, and recrudescence disease conditions. Available information about the roles that immunologic factors or their absence play in each of these conditions is presented, with emphasis being placed on diagnostic and serologic findings; and the potential for developing a vaccine against toxoplasmosis is discussed.

## REFERENCES

- (1) Frenkel, J. K., and A. Ruiz. Human toxoplasmosis and cat contact in Costa Rica. *Am J Trop Med Hyg* 29(6):1167-1180, 1980.
- (2) Frenkel, J. K., and O. E. Sousa. Antibodies to *Toxoplasma* in Panamanian mammals. *J Parasitol* 69:244-245, 1983.
- (3) Splendore, A. Un nuovo protozoo parasite dei conigli. (Incontrato nelle lesioni anatomiche d'una malattia che ricorda in molti punti il Kalazar dell'uomo.) *Rev Soc Scientifica São Paulo* 3:109-112, 1908.
- (4) Guimaraes, F. N. Toxoplasmose humana meningo-encefalomielite toxoplasmica; occorencia em adulto e em recém-nascido. *Mem Inst Oswaldo Cruz* 38:257-320, 1943.
- (5) Frenkel, J. K. Avances en toxoplasmosis. *Rev Lat Am Patol* 10:5-12, 1971.
- (6) Frenkel, J. K. *Toxoplasma* in and around us. *BioScience* 23:343-352, 1973.
- (7) Frenkel, J. K. Common questions on toxoplasmosis: Veterinary, medical, and public health considerations. *Vet Med Small Anim Clin* 77:1188-1196, 1982.
- (8) Sabin, A. B., and H. A. Feldman. Dyes as microchemical indicators of a new immunity phenomenon affecting a protozoan parasite (*Toxoplasma*). *Science* 108:660-663, 1948.
- (9) Schreiber, R. D., and H. A. Feldman. Identification of the activator system for antibody to *Toxoplasma* as the classical complement pathway. *J Infect Dis* 141(3):366-369, 1980.
- (10) Endo, T., and A. Kobayashi. *Toxoplasma gondii*: Electron microscopic study on the dye test reaction. *Exp Parasitol* 40(2):170-178, 1976.
- (11) Frenkel, J. K. Adoptive immunity to intracellular infection. *J Immunol* 98:1309-1319, 1967.
- (12) Frenkel, J. K., and D. W. Taylor. Toxoplasmosis in immunoglobulin M-suppressed mice. *Infect Immun* 38(1):360-367, 1982.
- (13) Hoff, R. L., and J. K. Frenkel. Cell-mediated immunity against *Besnoitia* and *Toxoplasma* in specifically and cross-immunized hamsters and in cultures. *J Exp Med* 139(3):560-580, 1974.
- (14) Lindberg, R. E., and J. K. Frenkel. Cellular immunity to *Toxoplasma* and *Besnoitia* in hamsters: Specificity and the effects of cortisol. *Infect Immun* 15:855-862, 1977.
- (15) Lindberg, R. E., and J. K. Frenkel. Toxoplas-

miosis in nude mice. *J Parasitol* 63:219-221, 1977.

(16) Frenkel, J. K., B. M. Nelson, and J. Arias-Stella. Immunosuppression and toxoplasmic encephalitis: Clinical and experimental aspects. *Hum Pathol* 6:97-111, 1975.

(17) Frenkel, J. K., M. Amare, and W. Larsen. Immune competence in a patient with Hodgkin's disease and relapsing toxoplasmosis. *Infection* 6(2):84-91, 1978.

(18) Borges, J. S., and W. D. Johnson. Inhibition of multiplication of *Toxoplasma gondii* by human monocytes exposed to T-lymphocyte products. *J Exp Med* 141(2):483-496, 1975.

(19) Anderson, S. E., S. Bautista, and J. S. Remington. Induction of resistance to *Toxoplasma gondii* in human macrophages by soluble lymphocyte products. *J Immunol* 117:381-387, 1976.

(20) Jones, T. C., H. Masur, L. Len, and T. L. C. Fu. Lymphocyte-macrophage interaction during control of intracellular parasitism. *Am J Trop Med Hyg* 26(6, Part 2):187-193, 1977.

(21) Shirahata, T., K. Schimizu, and N. Suzuki. Effects of immune lymphocyte products and serum antibody on the multiplication of *Toxoplasma* in murine peritoneal macrophages. *Z Parasitenkd* 49:11-23, 1976.

(22) Matsumoto, Y., H. Nagasawa, H. Sakurai, S. Sasaki, and N. Suzuki. Mouse spleen cell derived *Toxoplasma* growth inhibitory factor: Its effect on *Toxoplasma* multiplication in the mouse kidney cells. *Zentralbl Bakteriol [Orig A]* 250(3):383-391, 1981.

(23) Chinchilla, M., and J. K. Frenkel. Mediation of immunity to intracellular infection (*Toxoplasma* and *Besnoitia*) within somatic cells. *Infect Immun* 19:999-1012, 1978.

(24) Frenkel, J. K. Experimental analysis of tissue immunity in toxoplasmosis. *Lyon Médical* 248 (Suppl. No. 17):67-73, 1982.

(25) Remington, J. S., and T. C. Merigan. Interferon: Protection of cells infected with an intracellular protozoan (*Toxoplasma gondii*). *Science* 161(3843):804-906, 1968.

(26) Ahronheim, G. A. *Toxoplasma gondii*: Human interferon studies by plaque assay. *Proc Soc Exp Biol Med* 161:522-526, 1979.

(27) McLeod, R., and J. S. Remington. Studies on the specificity of killing of intracellular pathogens by macrophages. *Cell Immunol* 34(1):156-174, 1977.

(28) Wilson, C. B., V. Tsai, and J. S. Remington. Failure to trigger the oxidative metabolic burst by normal macrophages: Possible mechanism for survival of intracellular pathogens. *J Exp Med* 151(2):328-346, 1980.

(29) Nathan, C. F., H. W. Murray, M. E. Wiebe, and B. Y. Rubin. Identification of interferon-gamma as the lymphokine that activates human macrophage oxidative metabolism and antimicrobial activity. *J*

*Exp Med* 158:670-689, 1983.

(30) Pfefferkorn, E. R. Interferon gamma blocks the growth of *Toxoplasma gondii* in human fibroblasts by inducing the host cells to degrade tryptophan. *Proc Natl Acad Sci USA* 81(3):908-912, 1984.

(31) Bommer, W., H. H. Heunert, and B. Mithaler. Kinematographische Studien über die Eigenbewegung von *Toxoplasma gondii*. *Z Tropenmed Parasit* 20(4):449-458, 1969.

(32) Nichols, B. A., and R. G. O'Connor. Penetration of mouse peritoneal macrophages by the protozoan *Toxoplasma gondii*. *Lab Invest* 44(4):324-335, 1981.

(33) Frenkel, J. K., and S. A. Caldwell. Specific immunity and nonspecific resistance to infection: *Listeria*, protozoa, and viruses in mice and hamsters. *J Infect Dis* 131:201-209, 1975.

(34) Ruiz, A., and J. K. Frenkel. Intermediate and transport hosts of *Toxoplasma gondii* in Costa Rica. *Am J Trop Med Hyg* 29(6):1167-1180, 1980.

(35) Smithers, S. R., R. J. Terry, and D. J. Hockley. Host antigens in schistosomiasis. *Proc R Soc Biol* 171:483 and 494, 1969.

(36) Sergeant, E. Latent Infection and Premunition: Some Definitions of Microbiology and Immunology. In: P. C. C. Garnham, A. E. Pierce, and I. Roitt (eds.). *Immunity to Protozoa*. Blackwell, Oxford, 1963, pp. 39-47.

(37) Waldeland, H., and J. K. Frenkel. Live and killed vaccines against toxoplasmosis in mice. *J Parasitol* 69:60-65, 1983.

(38) Krahenbuhl, J. L., J. Ruskin, and J. S. Remington. The use of killed vaccines in immunization against an intracellular parasite: *Toxoplasma gondii*. *J Immunol* 108:425-531, 1972.

(39) Araujo, F. E., and J. S. Remington. Partially purified antigen preparations of *Toxoplasma gondii* protect against lethal infection in mice. *Infect Immun* 45:122-126, 1984.

(40) Elwell, M. R., and J. K. Frenkel. Immunity to toxoplasmosis in hamsters. *Am J Vet Res* 45(12):2668-2674, 1984.

(41) Waldeland, H., E. R. Pfefferkorn, and J. K. Frenkel. Temperature-sensitive mutants of *Toxoplasma gondii*: Pathogenicity and persistence in mice. *J Parasitol* 69:171-175, 1983.

(42) Elwell, M. R., and J. K. Frenkel. Acute toxoplasmosis in hamsters and mice: Measurement of pathogenicity by fever and weight loss. *Am J Vet Res* 45:2663-2667, 1984.

(43) Escajadillo, A., and J. K. Frenkel. Unpublished.

(44) Wilson, C. B., J. S. Remington, S. Stagno, and D. W. Reynolds. Development of adverse sequelae in children born with subclinical congenital *Toxoplasma* infection. *Pediatrics* 66(5):767-774, 1980.

(45) Lewis, W. P., and E. K. Markell. Acquisition

of immunity to toxoplasmosis by the newborn rat. *Exp Parasitol* 7(5):463-467, 1958.

(46) Dubey, J. P., and J. K. Frenkel. Cyst-induced toxoplasmosis in cats. *J Protozool* 19(1):155-177, 1972.

(47) Harboe, A., and S. Erichsen. Toxoplasmosis in chickens: III. Attempts to provoke a systemic disease by infection with a chicken strain and a human strain of *Toxoplasma*. *Acta Pathol Microbiol Scand* 35(5):495-502, 1954.

(48) Teutsch, S. M., D. D. Juranek, A. Sulzer, J. P. Dubey, and R. K. Sikes. Epidemic toxoplasmosis associated with infected cats. *N Engl J Med* 300:695-699, 1979.

(49) Benenson, M. W., E. T. Takafuji, S. W. Lemon, R. L. Greenup, and A. J. Sulzer. Oocyst transmitted toxoplasmosis associated with ingestion of contaminated water. *N Engl J Med* 307(11):666-669, 1982.

(50) Miller, N. L., J. K. Frenkel, and J. P. Duby. Oral infections with *Toxoplasma* cysts and oocysts in felines, other mammals and in birds. *J Parasitol* 58:928-937, 1972.

(51) Sousa, O. E., R. E. Saenz, and J. K. Frenkel. Toxoplasmosis in Panama. Unpublished.

(52) Dorfman, R. F., and J. S. Remington. Value of lymph-node biopsy in the diagnosis of acute acquired toxoplasmosis. *New Engl J Med* 289:878-881, 1973.

(53) Miettinen, M., L. Saxen, and E. Saxen. Lymph node toxoplasmosis. *Acta Med Scand* 208: 431-436, 1980.

(54) Roever-Bonnet, H. de, and H. C. Hillenbrink. The diagnosis of toxoplasmosis. *Trop Geogr Med* 18:38-47, 1966.

(55) Naot, Y., D. R. Guptill, and J. S. Remington. Duration of IgM antibodies to *Toxoplasma gondii* after acute toxoplasmosis. *J Infect Dis* 145(5):770, 1982.

(56) Miettinen, M. Histological differential diagnosis between lymph node toxoplasmosis and other benign lymph node hyperplasias. *Histopathology* 5:205-216, 1981.

(57) Sheagren, J. N., M. N. Lunde, and H. B. Simon. Chronic lymphadenopathic toxoplasmosis: A case with marked hyperglobulinemia and impaired delayed hypersensitivity responses during active infection. *Am J Med* 60(2):300-305, 1976.

(58) Sabin, A. B. Toxoplasmic encephalitis in children. *JAMA* 116(9):801-807, 1941.

(59) Pinkerton, H., and R. G. Henderson. Adult toxoplasmosis: A previously unrecognized disease entity simulating the typhus-spotted fever group. *JAMA* 116(9):807-814, 1941.

(60) Pinkerton, H., and D. Weinman. Toxoplasma infection in man. *Arch Pathol* 30:374-392, 1940.

(61) Kass, E. H., S. B. Andrus, R. D. Adams,

F. C. Turner, and H. A. Feldman. Toxoplasmosis in the human adult. *Arch Intern Med (Chicago)* 89:759-782, 1952.

(62) Gardner, I. D., and J. S. Remington. Aging and the immune response: II. Lymphocyte responsiveness and macrophage activation in *Toxoplasma gondii*-infected mice. *J Immunol* 120(3):944-949, 1978.

(63) Hemsath, F. A., and H. Pinkerton. Disseminated cytomegalic inclusion disease and disseminated toxoplasmosis in an adult with myeloid metaplasia. *Am J Clin Pathol* 26(1):36-41, 1956.

(64) Siegel, S. E., M. N. Lunde, A. H. Gelderman, R. H. Halterman, J. A. Brown, A. S. Levine, and R. G. Graw. Transmission of toxoplasmosis by leukocyte transfusion. *Blood* 37:388-394, 1971.

(65) Luft, B. J., Y. Naot, F. G. Araujo, E. B. Stinson, and J. S. Remington. Primary and reactivated *Toxoplasma* infection in patients with cardiac transplants: Clinical spectrum and problems in diagnosis in a defined population. *Ann Intern Med* 99(1): 27-31, 1983.

(66) Desmonts, G., and J. Couvreur. Congenital toxoplasmosis: A prospective study of 378 pregnancies. *N Engl J Med* 290:1110-1116, 1974.

(67) Eichenwald, H. F. A Study of Congenital Toxoplasmosis. In: J. Chr. Siim (ed.). *Human Toxoplasmosis*. Munksgaard, Copenhagen, 1960, pp. 41-49.

(68) Frenkel, J. K. Toxoplasmosis: Mechanisms of infection, laboratory diagnosis, and management. *Curr Top Pathol* 54:28-75, 1971.

(69) Frenkel, J. K., and S. Friedlander. *Toxoplasmosis: Pathology of Neonatal Disease—Pathogenesis, Diagnosis and Treatment*. U.S. Public Health Service Publication No. 141. U. S. Government Printing Office, Washington, D.C., 1951, 105 pp.

(70) Dubey, J. P., and J. K. Frenkel. Feline toxoplasmosis from acutely infected mice and the development of *Toxoplasma* cysts. *J Protozool* 23:537-546, 1976.

(71) Frenkel, J. K. Toxoplasmosis: Parasite Life Cycle, Pathology, and Immunology. In: D. M. Hammond and P. L. Long (eds.). *The Coccidia: Eimeria, Isospora, Toxoplasma and Related Genera*. University Park Press, Baltimore, 1973, pp. 343-410.

(72) Nicholson, D. H., and E. B. Wolchok. Ocular toxoplasmosis in an adult receiving long-term corticosteroid therapy. *Arch Ophthalmol* 94(2):248-254, 1976.

(73) Luft, B. J., F. Conley, J. S. Remington, M. Laverdie, K. F. Wagner, J. F. Levine, P. C. Craven, D. A. Strandberry, T. M. File, and N. Rich. Outbreak of central nervous system toxoplasmosis in Western Europe and North America. *Lancet* 1(8328):781-784, 1983.

(74) Ruskin, J., and J. S. Remington. Toxoplas-

mosis in the compromised host. *Ann Intern Med* 84(2): 193-199.

(75) Remington, J. S., and E. N. Cavanaugh. Isolation of the encysted form of *Toxoplasma gondii* from human skeletal muscle and brain. *N Engl J Med* 273:1308-1310, 1965.

(76) Frenkel, J. K., and D. D. Smith. Immunization of cats against shedding of *Toxoplasma* oocysts. *J Parasitol* 68(5):744-748, 1982.

(77) Frenkel, J. K., and D. D. Smith. Inhibitory effects of monensin on shedding of *Toxoplasma* oocysts by cats. *J Parasitol* 68(5):851-855, 1982.

(78) Frenkel, J. K. El tratamiento de la toxoplasmosis. In: Universidad de los Andes. *Simposio Interamericano de Toxoplasmosis*. ICFES, Serie de Memorias de Eventos Científicos Colombianos, No. 16. Instituto Colombiano para el Fomento de la Educación Superior (ICFES), Bogotá, 1984.

### FALCIPARUM MALARIA IN CANADA

In 1984, the Tropical Disease Unit at the Toronto General Hospital treated 38 patients with documented malaria, the largest annual number of cases seen in the past 10 years and a 125% increase over 1983. (Overall, 254 malaria cases were reported in Canada in 1984, as compared with a ten-year high of 600 cases in 1980 and a ten-year low of 65 in 1975.)

In addition, the proportion of Toronto General Hospital malaria patients infected with *P. falciparum* also increased, to 36.8%. Indeed, more cases (14) of *P. falciparum* malaria were seen in 1984 than in the previous five years combined.

Ten of the 14 falciparum patients had traveled in East Africa, two had traveled in West Africa, and two had come from India. Twelve patients were treated for presumed chloroquine-resistant falciparum malaria because they had visited known chloroquine-resistant areas (Kenya, the United Republic of Tanzania, Zambia, and Northeastern India). All of the patients responded to therapy, and no recrudescences occurred. For those requiring hospitalization, the average length of stay was 3.7 days.

NOTE: The marked increase in falciparum malaria seen in this unit is probably a reflection of increased exposure to drug-resistant *P. falciparum*. The number of travelers to Africa has not changed appreciably over the past 10 years, whereas the prevalence of chloroquine-resistant *P. falciparum* malaria has increased steadily. The proportion of cases of falciparum malaria acquired in Africa (85%) parallels data from the U.S. Centers for Disease Control showing that 72% of falciparum malaria cases imported into the United States were acquired in Africa. The unit's data further underline the high risk of acquiring falciparum malaria in East Africa, particularly when approved methods of chemoprophylaxis are not being followed.

Source: Ministry of Health and Welfare of Canada, *Canada Diseases Weekly Report* 11(24), 1985.