

A Review of Leishmaniasis in Ecuador¹

YOSHIHISA HASHIGUCHI² & EDUARDO A. GÓMEZ LANDIRES³



This article briefly reviews current knowledge about leishmaniasis in Ecuador—proceeding from 1920, when the first human case was described, to the present.

Regarding basic conditions, it appears that 14 of Ecuador's 20 provinces have endemic leishmaniasis. Nationally, over 4,000 cases were registered in the 1983–1986 period. Of 260 cases cited in the literature from 1920 through 1987, 240 (92.3%) were said to involve cutaneous forms of the disease and 18 (6.9%) mucocutaneous ones. Only one case each of visceral and diffuse cutaneous leishmaniasis was reported in 1920–1987, and neither of these has been confirmed.

Various Leishmania strains isolated by the authors from wild animals and man are currently being studied. To date, tests employing isoenzyme electrophoresis and monoclonal antibodies have identified some of the isolated strains as L. amazonensis and L. panamensis.

At present it seems evident that a detailed study of leishmaniasis transmission in Ecuador is needed in order to develop a plan for future control of the disease. Survey work directed at identifying the particular Leishmania varieties prevalent in the country's different endemic areas is also needed, as is research on the sandfly vectors and animal reservoirs of the disease.

Leishmaniasis was first reported in Ecuador in 1920 by Valenzuela (1). However, until recently it has remained one of the least studied of Ecuador's tropical diseases. For many years the main research on the disease involved clinical diagnosis, which eventually produced some confirmed case reports.

No well-organized medical registration system for leishmaniasis is available in Ecuador, a circumstance to which a variety of factors have contributed. To begin with, leishmaniasis in Ecuador, as in other South American countries, has al-

ways been a rural disease. Therefore, patients are usually poorly educated; some suffer benign infections that heal spontaneously, while others with longer, more chronic infections go to rural doctors who are unable to confirm the infections, primarily for lack of laboratory facilities, and can only make clinical diagnoses.

One result is that many cases registered as leishmaniasis may in fact be misdiagnosed cases of other problems such as anthrax, bacterial abscess, leprosy, paracoccidioidomycosis, sporotrichosis, skin cancer, or syphilis.

Double counting also occurs. Some registered patients are sent to city laboratories to have suspected leishmaniasis confirmed, where they are often registered again; and some positive cases are then sent to hospitals that frequently lack antimonials, but which are apt to register them a third time. Thus the same case may appear two or three times in statistical compilations.

¹Work on the review presented here was supported by a grant-in-aid for overseas scientific research from the Ministry of Education, Science, and Culture of Japan (Grant Nos. 61041059, 62043055, 63041096). This article has previously been published in Spanish in the *Boletín de la Oficina Sanitaria Panamericana*, 108(4):296–307, 1990.

²Department of Parasitology, Kochi Medical School, Nankoku City, Kochi 783, Japan.

³Department of Tropical Medicine, Faculty of Medicine, Universidad Católica Santiago de Guayaquil, Apartado 4671, Guayaquil, Ecuador.

On the other hand, many other cases are never registered. A substantial share of those afflicted may never consult a doctor; instead they consult anyone with past experience of the disease about the medicine to be used, and buy it if it is available. Such cases will never appear in the statistics. Therefore, as in many other South and Central American countries, leishmaniasis statistics in Ecuador do not closely reflect the actual incidence of the disease in the country, serving only to identify endemic foci or show where accidental vector-human contacts have occurred.

In sum, since 1920 many clinical cases have been diagnosed, and various clinical features of the disease have been discussed within the Ecuadorian medical community; but until very recently the manner in which leishmaniasis was transmitted, as well as the identity of its reservoirs and vectors, remained unknown.

HISTORICAL REVIEW

It is at present unclear whether leishmaniasis evolved independently as a zoonosis in the Old and New Worlds. In the past the continents were linked, and it is therefore difficult to hypothesize about the geographic origins of the disease. It is known, however, that the original parasite has diverged, adapting to different vectors and reservoirs in each hemisphere.

According to Ala-Vedra, who sought evidence of leishmaniasis in old Ecuadorian ceramics, the disease existed in Ecuador for hundreds or perhaps thousands of years before the arrival of Europeans. The fact that some pre-Columbian ceramics appear to show typical leishmanial lesions suggests that the disease was prevalent in that era (2). Ceramics from other Andean countries, such as Colombia and Peru, also suggest that

leishmaniasis was widespread in northwestern South America (3).

As already noted, serious transmission studies of leishmaniasis did not begin until 1982 (4–6). Nevertheless, from 1920 onward significant clinical and therapeutic research was conducted and a considerable amount of information was obtained. The following is a brief chronological account of important events in this history of leishmaniasis research:

In 1920 Valenzuela described the first recorded case, in a female patient with leishmanial ulcers on her forearm and thorax (1).

In 1924 Heinert reported the first case of mucocutaneous leishmaniasis in one of his patients at the general hospital in Guayaquil (7).

In 1928 Valenzuela reported a case of mucocutaneous leishmaniasis with osteoperiostitis, a diagnosis based on some X-ray films he had taken of the patient (8). This is the only record of this complication in a leishmaniasis patient from Ecuador.

In 1931 Trujillo reported a case of visceral leishmaniasis. The patient also had a single ulcer on his leg, from which no amastigote forms were isolated (9). This was the first report of visceral leishmaniasis in Ecuador, although it apparently represented an incorrect diagnosis. Valenzuela reported a new type of mucocutaneous leishmaniasis causing laryngeal ulcers, although no parasites were observed in smear specimens (10).

In 1945 Carrera reported the first case of leishmaniasis from Ecuador's Amazon region (11).

In 1949 León reported a case of visceral leishmaniasis—in a three-year-old boy from Esmeraldas Province. The patient's hepatic and splenic biopsies were reported positive (1). However, no other cases of visceral leishmaniasis have been reported from this or other areas of Ecuador to date.

In 1950 Rodríguez began the first taxonomic studies of Ecuadorian sandflies. He described a new species, *Phlebotomus camposi* (12).

In 1952 Ala-Vedra reported ceramic evidence pointing to pre-Columbian cases of the disease. He also described and listed clinical aspects of the disease and hypothesized about its transmission mechanisms, vectors, and reservoirs. Several chemotherapeutic treatments for Ecuadorian leishmaniasis were first considered and compared in his text (2). In that same year Rodríguez conducted a review of available knowledge on sandfly taxonomy, especially regarding *P. camposi* (13, 14).

In 1953 Rodríguez reported observation of *P. dysponetus in copula* in Ecuador (15). In addition, Rodríguez and Aviles made a bibliographic review of all known leishmanial cases in Ecuador, adding 29 cases that they themselves had diagnosed (16). They also evaluated Ecuadorian leishmaniasis research on the parasite, clinical aspects of the disease, vector taxonomy, and histopathologic diagnosis. They did not believe that the ceramic evidence was sufficient to suggest pre-Columbian existence of leishmaniasis, emphasizing that the involvement of indigenous American mammals as leishmanial reservoirs was a better argument. Rodríguez also described a new sandfly species, *P. leopoldoi*, which is still considered a valid species under the classification *Brumptomyia leopoldoi* (17).

In that same year Carrera reported seven cases of leishmaniasis from Suscal, Guayeturo, and Cochancay in Cañar Province, 800–1,000 m above sea level on the Andean slopes (18). All the smear specimens from the patients' ulcerous lesions were positive for *Leishmania* amastigotes. These cases were the first reported from Ecuador's Andean region. Carrera also named a number of suspected but uncon-

firmed vectors and reservoirs living in the area where the patients resided, after observing local ecologic conditions, and made some recommendations for epidemiologic surveillance and future control of the disease in Ecuador.

In 1954 León published an analysis on probable factors causing or predisposing to the mucosal lesions of American leishmaniasis, and on the probable mechanisms disseminating the agent from the skin to the mucous membranes. He also discussed the general clinical aspects of otic, rhinal, buccal, pharyngolaryngeal, and ophthalmic (palpebral) leishmaniasis found in the New World (19).

In 1956 Rodríguez described a new sandfly species, *P. guayasi*, and included a modified checklist of Ecuadorian sandflies (20). *P. guayasi* was later found to be synonymous with *Lutzomyia serrana*.

In 1960 Arzube recorded the occurrence of *P. sallesi* and *P. cayannensis cayannensis* in Ecuador for the first time (21).

In 1961 Zerega described a case of diffuse cutaneous leishmaniasis in Ecuador. The clinical, histopathologic, immunologic, and parasitologic aspects of the case received thorough study (22). No subsequent Ecuadorian cases of this kind have been recorded.

In 1962 Arzube published a tentative plan for investigating leishmaniasis in Ecuador's Esmeraldas Province. He made vector and human case surveys in different areas of the department and concluded that control measures should include poisoning wild animal reservoirs in their burrows (23).

In 1967 León presented a brief review of the cutaneous forms of leishmaniasis in children, based on the cases reported from different areas of Ecuador (24).

In 1969 Rodríguez reported a new focus of leishmaniasis in Los Bancos, a locale some 1,150 m above sea level in

Pichincha Province. He also made a brief survey of local sandfly fauna and presented some recommendations for controlling the disease (25).

In 1975 León modified the classification of clinical forms of American cutaneous leishmaniasis on the basis of personal experience and the published literature (26).

In 1978 Tafur and de Tafur devised a therapeutic assay for cutaneous leishmaniasis, using metronidazole, in Los Ríos Province (27). The preliminary results were good, but the treated patients were not followed for a long enough time to establish whether permanent cures had been achieved.

In 1979 León and León published an epidemiologic evaluation of nasal mucocutaneous leishmaniasis. They presented information on the diverse clinical aspects of this form of the disease and made recommendations for its treatment (28).

In 1981 Calero and de Coronel carried out an epidemiologic study of leishmaniasis in a village on the Andean slope where the disease was epidemic (29).

In 1982 Amunarriz made a careful study of human leishmaniasis cases in Ecuador's Amazon region. He studied the clinical forms and different treatments of the disease and undertook follow-up studies lasting two years or more (30). Also in 1982 the authors of the present article began research on leishmaniasis transmission in Ecuador. This was the first attempt to determine the vectors and reservoirs in leishmaniasis-endemic parts of the country. The research was directed primarily at establishing some pilot endemic areas for studying leishmaniasis transmission with special reference to reservoirs and vectors.

In 1984 Amunarriz published an abstract of his research on leishmaniasis in

Ecuador's Amazon region, with special reference to treatment of the patients. He followed up cases for a long period after treatment, lending credibility to his conclusions (31). Also in 1984 Hashiguchi et al. published the results of an epidemiologic survey on leishmaniasis performed in September 1982 at the "Cooperativa 23 de Febrero," a newly established plantation in the Andean region (32). The results indicated that leishmaniasis transmission had been occurring in a diverse array of the plantation's working and living areas. In addition, Young and Rogers provided a checklist of 49 sandfly species and subspecies found in Ecuador and made additional comments on some species (33). In their text, three closely related anthrophilic sandflies, *Lu. amazonensis*, *Lu. davisii*, and *Lu. clautrei*, all occurring in many parts of the Amazon Basin, are keyed and illustrated.

In 1985 Hashiguchi et al. published the results of studies done from 1982 to 1984 with special reference to vectors and reservoirs (4-6). Among six anthropophilic species of sandflies examined, two species (*Lu. trapidoi* and *Lu. hartmanni*) were implicated for the first time as probable vectors of leishmaniasis in Ecuador. Also, through examination of a considerable number of wild mammals, three probable reservoirs of the disease were identified; these naturally infected animals were the sloth *Choloepus hoffmanni didactylus*, the squirrel *Sciurus granatensis*, and the kinkajou *Potos flavus*. Some ecologic studies on the vector sandflies, such as their biting behavior and activity cycles, were also performed in leishmaniasis-endemic areas and were related to climatic conditions. Vertical sandfly distributions were also investigated at altitudes ranging from 350 m to 2,000 m above sea level along the road from Cochancay to Cuenca in Ocaña, Cañar Province.

In 1986 Calero et al. reported two cases of mucocutaneous leishmaniasis from Ecuador's Amazon region (34), and Ferreti et al. demonstrated a case of ganglionic leishmaniasis (35) that was thoroughly investigated and confirmed.

In 1987 Hashiguchi et al. reported the results of an epidemiologic survey of leishmaniasis at different altitudes of Ecuador's endemic areas on the Andean slope. These results suggested that the intensity of transmission was markedly influenced by the altitudes of human dwelling sites, as measured by natural infection rates of sandflies with *Leishmania* promastigotes at each site studied (36). That same year Mimori et al. examined the relationship between the severity of ulcerated lesions and immune responses in the early stage of cutaneous leishmaniasis in Ecuador; their findings suggested that the lesions' severity was proportionally related to activation of both the humoral and cell-mediated immune systems (37).

In 1989, for the first time in Ecuador, Mimori et al. examined *Leishmania* organisms isolated from mammals and humans. They reported the presence of at least two *Leishmania* species, *L. amazonensis* and *L. panamensis*, in the country (38).


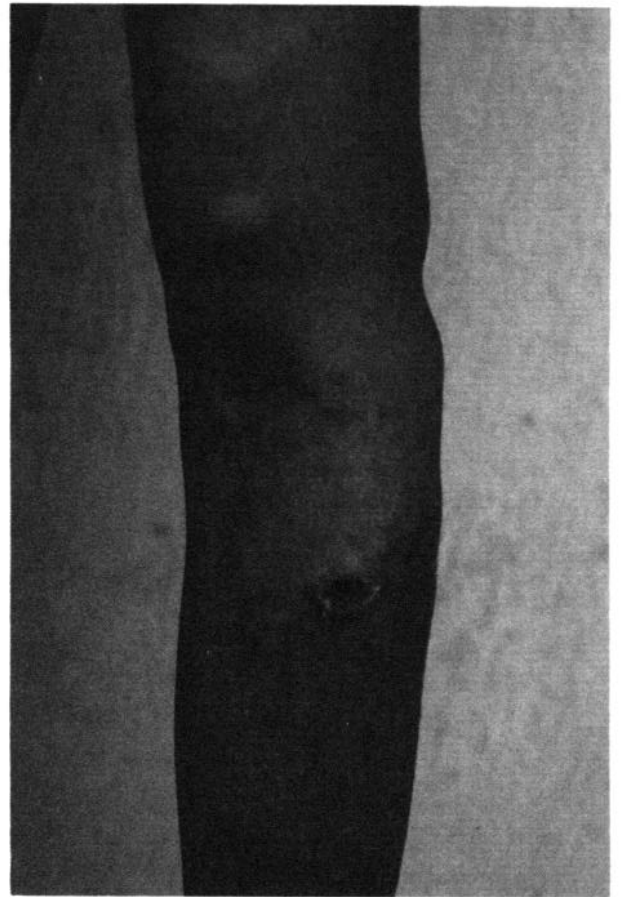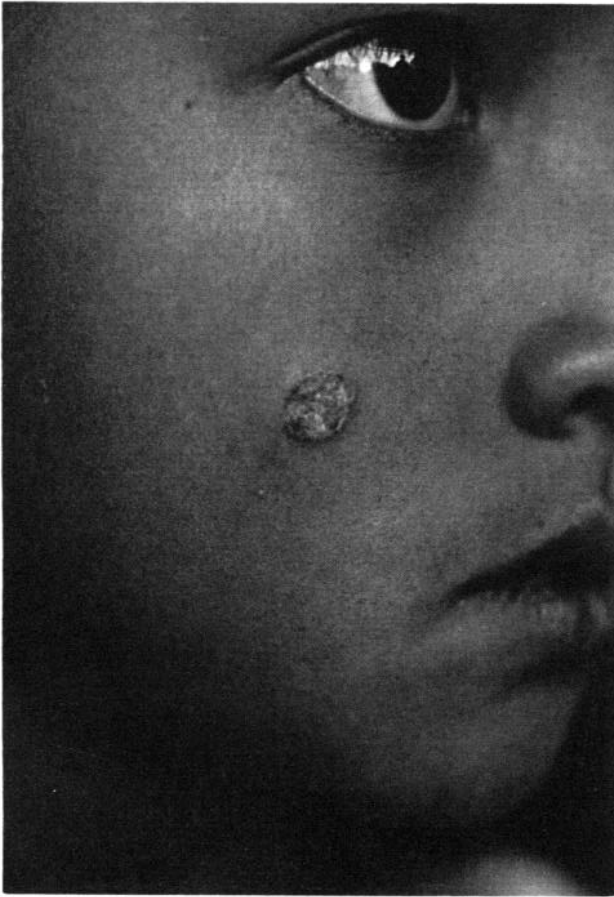
As the above indicates, from 1920 to 1981 Ecuadorian leishmaniasis research involved only clinical case studies, mostly of patients in city hospitals. Since 1982, however, studies have been conducted in leishmaniasis-endemic areas. These latter have involved collection of both data and samples for analysis; most of these samples are currently being subjected to a variety of tests—including isoenzyme electrophoresis, monoclonal antibody binding and k-DNA probe examinations, experimental infection of laboratory animals, and other laboratory studies.

GEOGRAPHIC CASE DISTRIBUTION

Leishmaniasis probably exists as a zoonosis in most parts of Ecuador's tropical and subtropical humid forest. Analysis of the data registered at the National Institute of Health and Tropical Medicine in Guayaquil and the results of our epidemiologic surveys indicate that there is a principal endemic area traversing Ecuador from north to south and forming a wide belt along the western slopes of the Andes. The disease is also endemic along the Pacific Coast and in Ecuador's Amazon region. In addition, a new type of leishmaniasis was recently observed in the Andean highlands at altitudes of 2,300–2,500 meters above sea level (39, 40). In all, 14 of Ecuador's 20 provinces have leishmaniasis-endemic regions, these 14 being Esmeraldas, Pichincha, Manabí, Guayas, Los Ríos, Bolívar, Cañar, Azuay, El Oro, Loja, Napo, Pastaza, Morona Santiago, and Zamora Chinchipe (Figure 1).

Regarding prevalence data, lack of an adequate system for registering epidemiologic information and the total absence of a surveillance and control program has meant that there are no statistical data on the incidence or prevalence of human leishmaniasis in Ecuador. From 1920 to 1952 there were only a few reports of human cases, the disease being little-known in the country at that time. From 1953 to 1987 most leishmaniasis studies were performed on human cases coming to health centers and general hospitals for care, though a few epidemiologic surveys were made in leishmaniasis-endemic areas (16, 25, 29–32, 36).

In the course of preparing this article we have compiled a partial statistical record in order to estimate the occurrence of leishmaniasis cases in each endemic area of the country. The cases included were



Top left photo: A case of Andean leishmaniasis in a six-year-old girl from Paute (Azuay Province, Ecuador). The subject, positive for *Leishmania mexicana* amastigotes, exhibits a superficial 10mm x 15mm lesion. *Top right:* A cutaneous leishmaniasis lesion with pronounced lymphadenitis on the left forearm of a male subject 19 years of age residing in Echandia (Bolívar Province). Four additional lesions on this subject's left elbow are not shown. *Bottom:* A view of Echandia (Bolívar Province, Ecuador), a settlement in a Pacific lowland area endemic for leishmaniasis. (Photos by Y. Hashiguchi.)

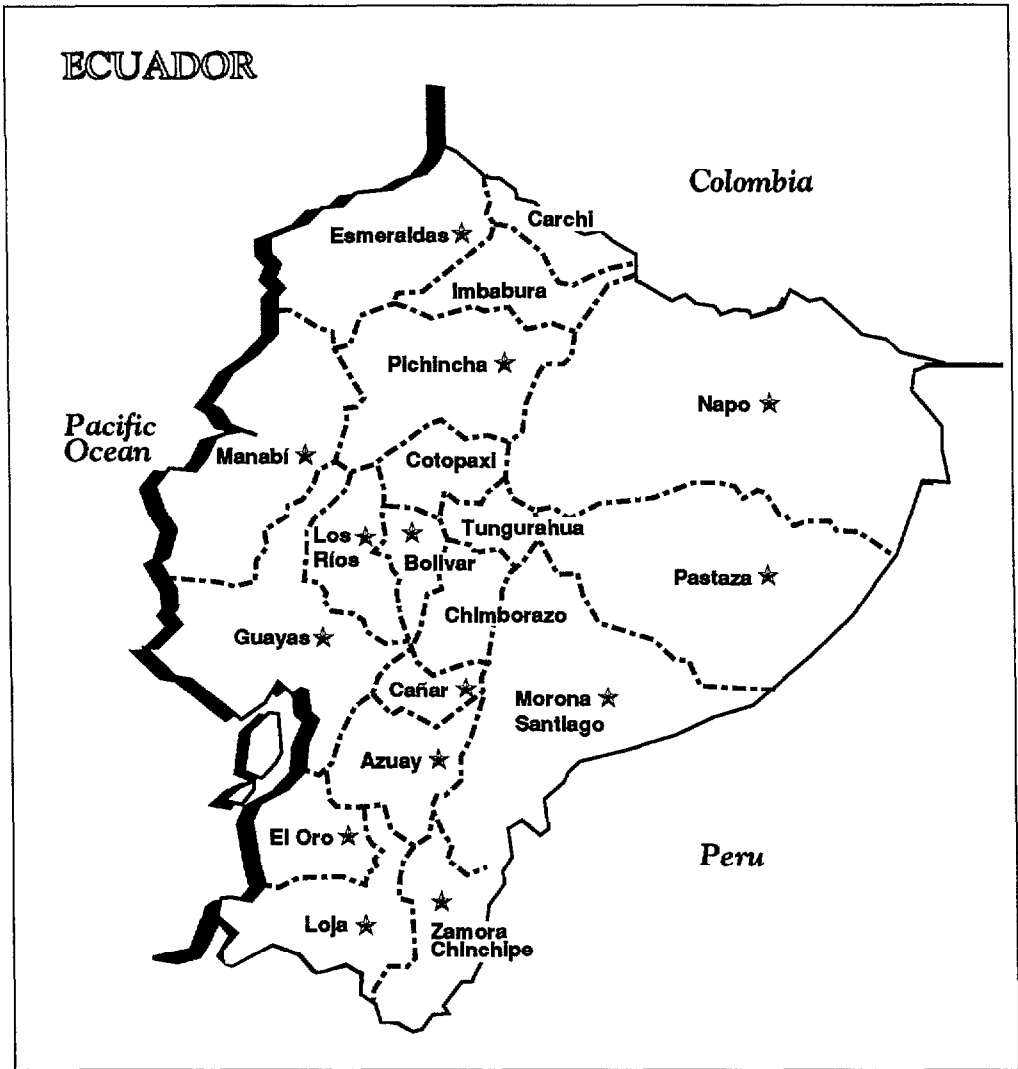

Figure 1. A map showing all of Ecuador's 20 provinces except Galápagos. Asterisks denote departments with endemic leishmaniasis.

diagnosed clinically and/or parasitologically, and were then registered at the Statistics Department of the National Institute of Health and Tropical Medicine and the Epidemiology Division Subsecretariat (Section II) of the Ministry of Health in Guayaquil (Table 1). Most of these cases had occurred in the provinces situated along the Pacific lowlands and western slopes of the Andes—most nota-

bly Esmeraldas, Pichincha, Manabí, Los Ríos, and Guayas.

CLINICAL CONSIDERATIONS

Clinical forms of leishmaniasis found in Ecuador have been mainly limited to cutaneous and mucocutaneous ones. As Table 2 shows, of 260 cases reported by type in the literature from 1920 through

Table 1. Leishmaniasis cases registered at the National Institute of Hygiene and Tropical Medicine and the Epidemiology Division Subsecretariat of the Ministry of Health of Ecuador, 1983–1986.

Province	Years				Total
	1983	1984	1985	1986	
Esmeraldas	220	270	295	307	1,092
Pichincha	150	110	210	215	685
Bolívar	—	—	—	24 ^a	24
Manabí	210	272	253	—	735
Los Ríos	12	8	391	73	484
Guayas	142	156	240	140	678 ^b
Cañar	95	—	—	—	95 ^b
Azuay	12	29	70	52	163
El Oro	1	4	—	—	5
Loja	5	22	—	1	28
Napo	7	5	12	17	41
Pastaza	7	11	9	6	33
Morona Santiago	11	—	—	1	12
Zamora Chinchipe	2	—	4	17	23
Total	874	887	1,484	853	4,098

^aFrom our unpublished data.

^bConsisting partly of our data (32, 36).

Table 2. Leishmaniasis cases reported by clinical disease form in principal Ecuadorian medical journals, 1920–1987. CL = cutaneous leishmaniasis; MCL = mucocutaneous leishmaniasis; DCL = diffuse cutaneous leishmaniasis; VL = visceral leishmaniasis; M = male; F = female; ? = patient's sex not cited.

Year	Total cases reported	Clinical disease form and sex of patients										Ref. nos.	
		CL			MCL			DCL		VL			
		M	?	F	M	?	F	M	F	M	F		
1920	2	1		1									1,16
1922	1				1								7,16
1925	1	1											16
1928	2	2											8,16
1931	2	1			1								9,16
1945	1	1											1,16
1949	3	2								1			1,16
1951	1			1									16
1952	14	9		4	1								2
1953	39	16	10	10	3								16,18
1961	1							1					22
1969	28	16		10	2								25
1978	13		13										27
1981	10	5		5									29
1982	32		22			10							30,31
1984	15	7		8									32
1987	95	32	31	32									32
Total	260	93	76	71	8	10		1		1			

1987, 240 (92.3%) were cutaneous and 18 (6.9%) were mucocutaneous.

Only one case each of the diffuse cutaneous and visceral forms have been reported to date, both of these reports being based on clinical diagnosis—without any parasitologic confirmation being provided by examination of smear specimens or cultures. There is thus insufficient evidence demonstrating the existence of these two forms in Ecuador, and more detailed investigations are required.

The case reported as visceral leishmaniasis in 1949 by León (1) came from an area of Esmeraldas Province endemic for the cutaneous form of the disease. To date, no other case of the visceral form has been reported from this area. Since the diagnosis was not confirmed by visceral biopsy and parasite isolation, it appears that the infection could have been the ordinary cutaneous form manifesting a visceral phase in an immunologically deficient patient.

The case of diffuse cutaneous leishmaniasis was reported in 1961 by Zerega (22), who stated that the clinical, immunologic, and histopathologic findings indicated this form of the disease. Unfortunately, however, no information was reported regarding the drug resistance usually found in cases with this form, nor was any parasite isolation performed for the purpose of obtaining a definitive diagnosis, though a biopsy specimen was positive for amastigotes. No further likely cases of diffuse cutaneous leishmaniasis have been reported in Ecuador to date.

TRANSMISSION STUDIES

Since the first diagnosed case of human leishmaniasis was reported in Ecuador, study of this disease has concentrated on clinical and therapeutic aspects,

and reports of many cases presenting various clinical features of the disease have been published. Unfortunately, these reports have not been followed by field research in endemic areas. Therefore, much of the knowledge of Ecuadorian leishmaniasis to date remains largely speculative.

The first studies dealing with leishmaniasis transmission in Ecuador were done by Rodríguez in 1950–1956 (12–15, 17, 20), and they were later followed by the contributions of Arzube (21) and Young and Rogers (33)—all of these being taxonomic studies of Ecuadorian sandflies (12–15, 17, 20, 21, 33). In all, 49 sandfly species and subspecies (including seven new species) were recorded (33). In 1982 we began research to investigate the transmission mechanism of leishmaniasis in endemic areas of Ecuador, with special reference to vectors and reservoirs; some of our data have already been published (4–6, 32).

Vectors

In 1982–1989 a survey of Ecuadorian leishmaniasis vectors was performed in different endemic areas, and 13 man-biting *Lutzomyia* species were collected using human bait (4, 6, 39, 40). Dissection of the collected sandflies showed that four species, *Lu. trapdoi*, *Lu. gomezi*, *Lu. ayacuchensis*, and *Lu. hartmanni*, were naturally infected with *Leishmania* promastigotes (4, 39, 40). The nine other collected species, which have not yet been implicated in transmission, are *Lu. panamensis*, *Lu. hirusta hirusta*, *Lu. shannoni*, *Lu. osornoi*, *Lu. nevesi*, *Lu. carrerai thula*, *Lu. carrerai carrerai*, *Lu. yuilli*, and *Lu. ser-rana*. The first two of these have been implicated as vectors of leishmaniasis in neighboring countries. In this vein, it should be noted that some of the other sandfly species previously reported in

Ecuador (i.e., *Lu. flaviscutellata*, *Lu. olmeca bicolor*, *Lu. ylephiletor*, and *Lu. paraensis*) have been also implicated as vectors of the disease in other countries.

With regard to the four Ecuadorian species in which infections were observed, *Lu. trapidoi* and *Lu. gomezi* have been implicated as vectors in other South American countries, but detection of *Leishmania* promastigotes in *Lu. hartmanni* and *Lu. ayacuchensis* represents the first time these species have been implicated as vectors of New World leishmaniasis.

Reservoirs

A survey of Ecuadorian leishmaniasis reservoirs was initiated in 1982, when the vector research was also done. Forty-eight wild mammals belonging to 12 species and 12 genera were caught in two leishmaniasis-endemic areas, Naranjal (Guayas Province) and Ocaña (Cañar Province), and were examined for leishmanial parasites (5). Three mammalian species—the sloth *Choloepus hoffmanni didactylus* (this species was misidentified as *Bradypus variegatus ephippiger* in our original text), the squirrel *Sciurus granatensis*, and the kinkajou *Potos flavus*—tested positive for the parasites, while the others—*Didelphis marsupialis*, *Tamandua tetradactyla*, *Sylvilagus brazilensis*, *Dasybus novemcinctus*, *Proechimys semispinosus* (*Rattus spinosus*), *Rattus rattus*, *Coendou bicolor*, *Agouti paca*, and *Dasyprocta punctata*—yielded negative results. The isolates obtained are still under study. More recently, three wild animals, a specimen of *Sciurus vulgaris* from Palenque (Los Ríos Province) and specimens of *Potos flavus* and *T. tetradactyla* from Echeandia (Bolívar Province), were found to be positive for the parasite; the organisms isolated from these animals have been identified as *L. amazonensis* (38).

PARASITE ISOLATIONS

Since 1920 many attempts have been made to isolate *Leishmania* from human lesions in Ecuador. Until recently, these yielded no positive results. However, during 1982 and 1988 we were able to collect a considerable number of *Leishmania* organisms from humans and wild mammals. The circumstances of these parasite isolations have been described previously (5, 39, 40).

For the first time in Ecuador, some of our isolates were characterized by using isoenzyme electrophoresis and monoclonal antibodies. This process identified isolates from three wild animals as being *L. amazonensis*, as noted above. Another isolate, from the cutaneous lesion of a human subject living in Santo Domingo de los Colorados (Pichincha Province), has been identified as *L. panamensis* (38); and three other species of the parasite (*L. mexicana*, *L. braziliensis*, and *L. guyanensis*) have recently been isolated from Ecuadorian patients with the disease (40, 41). However, a number of remaining isolates are currently under study, and some of the parasites involved appear to be different from the currently well-established New World *Leishmania* species (38, 40).

DIAGNOSIS

Direct parasite detection using smears from ulcerous lesions or nodules is the principal method used to diagnose leishmaniasis in Ecuador. However, such work has only been performed at a few Ecuadorian medical centers. Rural doctors rarely use this technique, and many cases of dermal lesions have therefore been treated for leishmaniasis without differential diagnosis when drugs are available. Immunologic diagnosis has not been routinely performed in the country, but skin testing (Montenegro's test)

using promastigote antigen prepared by the method of Reed et al. (42) has recently been employed as a diagnostic tool at the National Institute of Health and Tropical Medicine in Guayaquil, with good results.

TREATMENT

Antimonials are regularly used in Ecuador to treat leishmaniasis patients. Gulcantime® (meglumine antimonate) seems to be the most effective drug, though Fuadin® (stibophen B.P.) is probably equally potent. Repodral® (stibophen) is also sometimes used in Ecuador to treat leishmaniasis. Other drugs, such as amphotericin B (Fungizone®), pyrimethamine, and Lampit® are used occasionally, with some satisfactory results being reported. A few doctors in Ecuador have used Metronidazol® for leishmaniasis treatment and have reported some good results (27); however, this drug may only be acting as an antiinflammatory agent, since there is no known biochemical mechanism that would qualify it as a curative agent (43).

In general, therapeutic assays with a correspondent follow-up of patients for a long period have not as yet been done in Ecuador. Amunarriz has published data on a carefully designed therapeutic research procedure using antimonials and five kinds of traditional Amazonian Indian medicines (31). His information on the effectiveness of the Indian treatments against leishmaniasis is noteworthy. However, it will be necessary to study more cases treated with Indian medicines before any definitive conclusions can be reached.

COMMENTS

Review of past leishmaniasis research in Ecuador reveals one clear fact: For

many years prime attention was paid to clinical and therapeutic aspects of the disease; and aside from some sporadic attempts, research on leishmaniasis transmission was ignored. It also seems evident that a detailed study of leishmaniasis transmission is necessary in order to obtain enough information to develop a plan for future control of the disease.

Several Ecuadorian stocks of *Leishmania* have already been isolated from animals and man. As noted above, examination of these isolates has shown that five *Leishmania* species—*L. amazonensis*, *L. mexicana*, *L. braziliensis*, *L. guyanensis*, and *L. panamensis*—are in the country at present. Such survey work should be continued in order to further delineate the causative agent or agents of leishmaniasis throughout the country. Work of this nature should make special efforts to isolate the parasite from vector sandflies.

The biology of the implicated vectors, *Lu. trapidoi*, *Lu. gomezi*, *Lu. ayacuchensis*, and *Lu. hartmanni*, should be extensively studied. Fortunately, progress we have made in the laboratory rearing of sandflies will permit us to investigate this in detail.

To date five wild animals (*Choloepus h. didactylus*, *Potos flavus*, *Sciurus granatensis*, *S. vulgaris*, and *Tamandua tetradactyla*) have been found naturally infected with *Leishmania* in Ecuador. Future studies should be made to determine their true and potential roles as reservoirs in all leishmaniasis-endemic areas.

Acknowledgments. We are grateful to Dr. Bryce C. Walton for his critical reading of the manuscript. Thanks are also extended to our Ecuadorian colleagues who have generously enabled us to use all available facilities at the National Institute of Health and Tropical Medicine (NIHTM)—and especially to Dr. Vicenta V. de Coronel, Dr. Guarberto Avalos Z.

(Director, NIHTM), and the skillful staff at the NIHTM Library.

REFERENCES

1. Rodríguez JD. *Lecciones de parasitología humana: género Leishmania*. 5th ed. Guayaquil: Universidad de Guayaquil; 1974: 170-85.
2. Ala-Vedra JT. El botón de Oriente en el Ecuador. Paper presented at the IV Congreso de Medicina y I de Cirugía Ecuatorianos, I. *Jornada Pediátrica Ecuatoriana*. Guayaquil: Universidad de Guayaquil; 1952:1-23.
3. Werner KJ, Barreto P. Leishmaniasis in Colombia: a review. *Am J Trop Med Hyg*. 1981;30:751-61.
4. Hashiguchi Y, Gómez EAL, de Coronel VV, et al. Natural infections with promastigotes in man-biting species of sand flies in leishmaniasis-endemic areas of Ecuador. *Am J Trop Med Hyg*. 1985; 34:440-46.
5. Hashiguchi Y, Gómez EAL, de Coronel VV, et al. *Leishmania* isolated from wild mammals caught in endemic areas of leishmaniasis in Ecuador. *Trans R Soc Trop Med Hyg*. 1985;79:120-21.
6. Hashiguchi Y, Gómez EAL, de Coronel VV, et al. Biting activity of two anthropophilic species of sandflies, *Lutzomyia*, in an endemic area of leishmaniasis in Ecuador. *Ann Trop Med Parasitol*. 1985;79:533-38.
7. Heinert JF. Un caso de leishmaniasis cutaneomucosa. *An Soc Med-Quir Guayas*. 1924;3:450-51.
8. Valenzuela AJ. [Sobre leishmaniasis] en la Sociedad Médico-Quirúrgica del Guayas: sección científica de agosto de 1928. *An Soc Med-Quir Guayas*. 1931;11:410.
9. Trujillo P. [Sobre leishmaniasis] en la Sociedad Médico-Quirúrgica del Guayas: sección del 14 de agosto de 1931. *An Soc Med-Quir Guayas*. 1931;11:410.
10. Valenzuela AJ. Leishmaniasis laringea. *An Soc Med-Quir Guayas*. 1931;11:287.
11. Carrera CT. Leishmaniasis cutaneo mucosa. *Rev Asoc Med Cuenca*. 1945;6:23.
12. Rodríguez JD. Los *Phlebotomus* del Ecuador: 1, consideraciones generales. *Rev Ecuat Hig Med Trop*. 1950;7:1-10.
13. Rodríguez JD. Los *Phlebotomus* del Ecuador. *Rev Ecuat Hig Med Trop*. 1952;8-9:15-18.
14. Rodríguez JD. Notas adicionales sobre la especie ecuatoriana *Phlebotomus (Pressatia) camposi* Rodríguez, 1952. *Rev Ecuat Entomol*. 1953;1(2):91-96.
15. Rodríguez JD. Observación del *P. dysponetus* Fairchild y Hertig, 1952, en copula. *Rev Ecuat Hig Med Trop*. 1953;10:25-26.
16. Rodríguez JD, Aviles F. Algunas observaciones sobre leishmaniasis cutaneomucosa en el Ecuador. *Rev Ecuat Hig Med Trop*. 1953;10:35-58.
17. Rodríguez JD. Los *Phlebotomus* del Ecuador (Diptera, Psychodidae). *Rev Ecuat Hig Med Trop*. 1953;10:51-55.
18. Carrera CT. Anotaciones sobre la leishmaniasis selvática americana o cutaneo-mucosa. *Rev Ecuat Entomol Parasitol*. 1953;1:76-90.
19. León LA. La *Leishmania braziliensis* Viana, 1911 y las leishmaniasis otorrino-buco-faringolaríngea y oftálmica. *Rev Ecuat Entomol Parasitol*. 1954;2:15-28.
20. Rodríguez JD. Los *Phlebotomus* del Ecuador (Diptera, Psychodidae). *Rev Ecuat Hig Med Trop*. 1956;13:75-80.
21. Arzube MER. Los *Phlebotomus* del Ecuador (relato de capturas no publicadas). *Rev Ecuat Hig Med Trop*. 1960;17:155-159.
22. Zerega F. Sobre un caso de leishmaniasis tegumentaria difusa. *Rev Ecuat Hig Med Trop*. 1961;18:17-20.
23. Arzube MER. Plan tentativo de investigación de leishmaniasis sudamericana en la Provincia de Esmeraldas, Ecuador. *Rev Ecuat Hig Med Trop*. 1962;19:79-83.
24. León LA. Leishmaniasis tegumentaria en los niños. In: *Reimpreso de homenaje a Aldo Muggia, volumen jubilar*. Quito: Editorial Universitaria; 1967:1-31.
25. Rodríguez JD. Leishmaniasis muco cutanea en la Provincia de Pichincha. *Rev Ecuat Hig Med Trop*. 1969;26:3-7.
26. León LA. Formas clínicas de la leishmaniasis tegumentaria americana. *Pren Med Argent*. 1975;62:73.
27. Tafur A, de Tafur C. *Evaluación terapéutica del Metronidazol (Acromona) en la leishmaniasis cutanea*. Guayaquil: Offset ABAD; 1978:3-10.
28. León LA, León R. *Las rinopatías en la leishmaniasis tegumentaria americana*. Quito: Editorial Universitaria; 1979:1-16.

29. Calero G, de Coronel VV. Estudio de la leishmaniasis cutanea en un asentamiento agrícola precordillerano. *An Med Cir.* 1981;4:28-32.
30. Amunarriz M. Leishmaniasis. In: *Salud y enfermedad: patología tropical en la región amazónica*. Napo, Ecuador: Ediciones CIC-AME, Prefectura Apostólica de Aguarico; 1982:73-88.
31. Amunarriz M. *Leishmaniasis en la región amazónica*. Napo, Ecuador: Ediciones CIC-AME, Prefectura Apostólica de Aguarico; 1984:1-35.
32. Hashiguchi Y, de Coronel VV, Gómez EAL. An epidemiological study of leishmaniasis in a plantation "Cooperativa 23 de Febrero" newly established in Ecuador. *Jpn J Parasitol.* 1984;33:393-401.
33. Young DG, Rogers TE. The phlebotomine sand fly fauna (Diptera: Psychodidae) of Ecuador. *J Med Entomol.* 1984;21:597-611.
34. Calero G, Heinert JM, Martínez RL. Leishmaniasis cutaneo mucosa: reporte de dos casos de la amazonia ecuatoriana. *Dermatol Ecuat.* 1986;1:26-29.
35. Ferretti HZ, de Ferretti MIB, de Ramírez B. Leishmaniasis ganglionar: reporte de un caso. *Dermatol Ecuat.* 1986;1:30-34.
36. Hashiguchi Y, Gómez EAL, de Coronel VV, et al. Leishmaniasis in different altitudes on Andean slope of Ecuador. *Jpn J Trop Med Hyg.* 1987;15:7-15.
37. Mimori T, Hashiguchi Y, Kawabata M, et al. The relationship between severity of ulcerated lesions and immune responses in the early stage of cutaneous leishmaniasis in Ecuador. *Ann Trop Med Parasitol.* 1987;81:681-85.
38. Mimori T, Grimaldi Jr G, Kreutzer RD, et al. Identification of *Leishmania* isolates from humans and wild animals in Ecuador, using isoenzyme electrophoresis and monoclonal antibodies. *Am J Trop Med Hyg.* 1989;40:156-60.
39. Hashiguchi Y. *Studies on New World leishmaniasis and its transmission, with particular reference to Ecuador*. Kochi, Japan: Kyowa Printing; 1987:1-174. (No 1).
40. Hashiguchi Y. *Studies on New World leishmaniasis and its transmission, with particular reference to Ecuador*. Kochi, Japan: Kyowa Printing; 1990:1-238. (No 2).
41. Armijos RX, Chico ME, Cruz ME, et al. Human cutaneous leishmaniasis in Ecuador: identification of parasites by enzyme electrophoresis. *Am J Trop Med Hyg.* 1990;42:424-28.
42. Reed SG, Badaro R, Masur H, et al. Selection of a skin test antigen for American visceral leishmaniasis. *Am J Trop Med Hyg.* 1986;35:79-85.
43. Walton BC, Paulson JE, Arjona MA, et al. American cutaneous leishmaniasis. *JAMA.* 1974;228:1256-58.